

Nodding syndrome in Ugandan children – clinical features, brain imaging and complications: a case series

Richard Idro,^{1,2} Robert Opika Opoka,¹ Hellen T Aanyu,¹ Angelina Kakooza-Mwesige,¹ Theresa Piloya-Were,¹ Hanifa Namusoke,¹ Sarah Bonita Musoke,¹ Joyce Nalugya,³ Paul Bangirana,³ Amos Deogratius Mwaka,⁴ Steven White,⁵ Kling Chong,⁶ Anne D Atai-Omoruto,⁷ Edison Mworozzi,¹ Jolly Nankunda,¹ Sarah Kiguli,¹ Jane Ruth Aceng,⁸ James K Tumwine¹

To cite: Idro R, Opoka RO, Aanyu HT, *et al.* Nodding syndrome in Ugandan children—clinical features, brain imaging and complications: a case series. *BMJ Open* 2013;**3**:e002540. doi:10.1136/bmjopen-2012-002540

► Prepublication history for this paper are available online. To view these files please visit the journal online (<http://dx.doi.org/10.1136/bmjopen-2012-002540>).

Received 27 December 2012
Revised 5 April 2013
Accepted 8 April 2013

This final article is available for use under the terms of the Creative Commons Attribution Non-Commercial 2.0 Licence; see <http://bmjopen.bmj.com>

For numbered affiliations see end of article.

Correspondence to
Dr Richard Idro;
rido1@gmail.com

ABSTRACT

Objectives: Nodding syndrome is a devastating neurological disorder of uncertain aetiology affecting children in Africa. There is no diagnostic test, and risk factors and symptoms that would allow early diagnosis are poorly documented. This study aimed to describe the clinical, electrophysiological and brain imaging (MRI) features and complications of nodding syndrome in Ugandan children.

Design: Case series.

Participants: 22 children with nodding syndrome brought to Mulago National Referral Hospital for assessment.

Outcome measures: Clinical features, physical and functional disabilities, EEG and brain MRI findings and a staging system with a progressive development of symptoms and complications.

Results: The median age of symptom onset was 6 (range 4–10) years and median duration of symptoms was 8.5 (range 2–11) years. 16 of 22 families reported multiple affected children. Physical manifestations and complications included stunting, wasting, lip changes and gross physical deformities. The bone age was delayed by 2 (range 1–6) years. There was peripheral muscle wasting and progressive generalised wasting. Four children had nodding as the only seizure type; 18 in addition had myoclonic, absence and/or generalised tonic-clonic seizures developing 1–3 years after the onset of illness. Psychiatric manifestations included wandering, aggression, depression and disordered perception. Cognitive assessment in three children demonstrated profound impairment. The EEG was abnormal in all, suggesting symptomatic generalised epilepsy in the majority. There were different degrees of cortical and cerebellar atrophy on brain MRI, but no hippocampal changes. Five stages with worsening physical, EEG and brain imaging features were identified: a prodrome, the development of head nodding and cognitive decline, other seizure types, multiple complications and severe disability.

Conclusions: Nodding syndrome is a neurological disorder that may be characterised as probably symptomatic generalised epilepsy. Clinical manifestations and complications develop in stages

ARTICLE SUMMARY

Article focus

- This paper offers detailed descriptions of the clinical features and complications of nodding syndrome in Ugandan children and the electrophysiological and brain imaging features.
- It also proposes a clinical staging system for the disease.

Key messages

- Nodding syndrome is an epidemic neurological disorder affecting children in parts of sub-Saharan Africa that may be characterised as a probable symptomatic generalised epilepsy with features of epileptic encephalopathy.
- Patients progressively develop both physical and functional deficits including multiple seizure types, cognitive and physical decline, malnutrition and psychiatric features. Five clinical stages could be identified.
- The proposed clinical stages are associated with worsening cortical and cerebellar atrophy on brain imaging and more severe epileptiform and background EEG changes. These stages may be useful in guiding treatment and rehabilitation.

Strengths and limitations of this study

- Although the sample size is small and there is no comparison group, this is one of the few studies so far to have carefully documented the clinical features and complications of nodding syndrome combined with extensive electrophysiology and brain imaging data, describe the natural history and the first to provide a staging system. The study patients, however, may not be representative of the population, as they were not randomly drawn from the community.
- The study did not investigate the aetiology and the proposed staging was mainly derived from parental descriptions rather than prospective observations and, therefore, suffers from recall bias.
- The resolution of our brain MRI is quite low.

which might be useful in defining treatment and rehabilitation. Studies of risk factors, pathogenesis, management and outcome are urgently needed.

BACKGROUND

Nodding syndrome is a devastating neurological disorder of uncertain aetiology described in African children.¹ It was first described in Tanzania in 1960s² and subsequent reports have come from Liberia,³ South Sudan⁴⁻⁶ and Uganda.⁷⁻⁸ The syndrome is characterised by head nodding determined to be atonic seizures⁸ often occurring in association with feeding, a cold breeze or cold weather, and complicated by other seizure types, malnutrition and cognitive decline.⁶⁻⁹⁻¹⁰

In Uganda, almost all affected individuals are from the north of the country where there are an estimated 3000 cases. The region, for the past 20 years, had instability from rebel activity.¹¹ As a result, the population was internally displaced into densely populated camps. It is only in the last 5 years that peace returned and the population returned to their homes. This region is crossed by two rivers—the *Aswa* and *Pager* Rivers, has high malaria transmission and is endemic for *Onchocerca volvulus*. This parasite has variously been associated with the *Nakalanga* syndrome (a tropical syndrome characterised by short stature and malnutrition),¹²⁻¹⁵ epilepsy¹⁶⁻¹⁷ and nodding syndrome.⁵⁻⁹ This association has, however, been indirect as no *O. volvulus* contamination of cerebrospinal fluid has been documented.¹⁸

There are only limited descriptions of nodding syndrome.⁴⁻⁵⁻⁸⁻¹⁰ Winkler *et al*⁹ provided the most detailed account of the syndrome to date, describing clinical features in 62 Tanzanian patients and classifying them as either head nodding only or head nodding plus, if they also had other seizure types. Initial symptoms allowing early recognition of the disease, its natural history and potentially modifiable risk factors are poorly characterised. There is no diagnostic test and the current case definition is based solely on clinical criteria. The objective of this study was to describe the clinical, electrophysiological and brain imaging features and complications of nodding syndrome in Ugandan children and to propose a staging system.

METHODS

Design and setting

This is a case series of 22 Ugandan children with nodding syndrome. The study was conducted in Mulago, the National Referral Hospital in Uganda and teaching hospital for Makerere University College of Health Sciences in Kampala. This hospital provides tertiary level care for patients in a country in which most public healthcare services are paid for by the state.

Participants

Participants were patients with suspected nodding syndrome brought by the Ministry of Health from Kitgum district near the border with South Sudan, to Mulago Hospital in March 2012 for specialist assessments to better understand the syndrome. Kitgum district is the epicentre of the disease and one of the most affected districts in the country. Of the 25 patients brought to Mulago, 1 young adult (a 23-year-old man was found to have a brain tumour) and 2 adolescents (an 18-year-old girl with a cerebellar hypoplasia syndrome and a 16-year-old boy with a history of cerebral malaria at the age of 4 years and subsequent neurological sequelae) were excluded. The remaining 22 children had probable nodding syndrome and were included in the study. A case of probable nodding syndrome was defined as

- ▶ A child older than 2 years or an adolescent who previously was developing normally.
- ▶ Two or more episodes of recurrent head nodding occurring spontaneously or consequent to the sight of food or coldness.
- ▶ With or without other types of seizures, neurological signs, regression in growth or learning disability.

This case definition was revised during the International Meeting on Nodding Syndrome later in 2012. However, all selected patients fulfilled the revised criteria.¹⁹

Permission for the study was obtained from Makerere University School of Medicine Research and Ethics Committee. However, as we had no study protocol prior to the arrival of the patients, clinical care and assessment followed the hospital's standard procedures for routine non-surgical care for children. Verbal parental consent was obtained for all clinical, laboratory and imaging procedures. As is policy, however, parents gave written consent for photography, as this is considered over and above routine care and for any surgical procedures. Parents were specifically made aware that the objective of the assessments was not a cure for the disease, but a better understanding of the disease and that the general findings from the evaluation of the group of patients with nodding syndrome would be made available to the wider scientific community in presentations and publications, with a specific aim of improving the care for people affected by the disorder in the future. To this effect, a submission was then made to the Ethics Committee and permission to use results of the investigations was subsequently granted.

Study measurements and procedures

All had detailed clinical, electrophysiological and brain imaging assessments and laboratory testing.

Clinical assessment

The history included an enquiry about the time from pregnancy to the onset and the progressive development of symptoms, physical and functional difficulties. The clinical examination included general, nutritional, neurological,

cognitive and mental state assessments. Wasting was defined as weight for height Z score of <-2 and stunting as height for age Z score of <-2 . Sexual maturity was assessed using the Tanner Sexual Maturity staging. Patients were classified as having nodding syndrome only or nodding syndrome plus depending on whether they also had other seizure types.⁹ x-Rays of the left wrist were taken for bone age and reported using a Greulich and Pyle Atlas by a blinded radiologist.²⁰ Bone growth was considered delayed if it was 2 years below the chronological age. Cognitive functioning was assessed in detail in four children—median age 14.5 (range 13–15) years—2 weeks after the initiation of sodium valproate using the Kaufman Assessment Battery for Children 2nd Edition (KABC-2). This test has previously been adapted for use in Uganda.²¹ All four had symptoms for longer than 5 years.

Laboratory procedures

Ten millilitres of blood was drawn for full blood count, erythrocyte sedimentation rate (ESR), malaria parasites, electrolytes, liver and renal function tests and HIV testing. Cerebrospinal fluid was examined for cells, glucose, protein, microscopy and bacteriological culture. In addition, 10 children had a skin snip examined for *O. volvulus* as previously described.⁹

Neurophysiology and imaging

All had a 30-min EEG recording with an XLTEK EEG system (Optima Medical Ltd, London, UK) using the 10–20 electrode placement system, which was reviewed by a consultant clinical neurophysiologist (SW) in the UK. Brain MRI in T1, T2 and Flair sequences were obtained without contrast in 19/22 patients using a 0.5 Tesla machine (BASDA Medical Apparatus, Guangzhou) and the images were also examined in the UK by a Consultant Neuroradiologist (KC).

Natural history and staging

At the end of the first week, after the patients and carers had acclimatised to the referral hospital environment, the attending clinician sat with each carer and obtained detailed histories of the progressive development and timing of symptoms and complications of nodding syndrome to characterise the natural history. A standardised proforma with a diagrammatic representation of possible events and a linear timeline was used to obtain these descriptions. Information from each patient was plotted on the timeline and later combined with the data from other patients to identify emerging patterns, from which the proposed stages of the disorder were derived.

Treatment

The patients were started on symptomatic treatment (sodium valproate for seizure control, nutritional and physical therapy, counselling and social support) according to the national guidelines developed a month earlier.²² In this protocol, all received sodium valproate starting at 10 mg/kg/day. The dose was titrated in

5–10 mg/kg/day increases according to the level of seizure control. Nutritional rehabilitation included Ready to Use Therapeutic Foods (Plumpy'Nut, Nutriset, Malaunay) and locally prepared food. Occupational and physiotherapy, family counselling and support were provided as appropriate.

Data analysis

Data were analysed using STATA V.12 (STATA Corp, Texas, USA). Results are summarised as frequencies, proportions and medians as appropriate. The clinical features, complications and disability were then used to describe treatment and rehabilitation needs. Clinical stages were identified and brain imaging and EEG correlated with the clinical stages.

RESULTS

General features

Nine patients (40.9%) were men. The age range was 12–18 years. The median age at onset of symptoms was 6 (range 4–10) years and the median duration of symptoms was 8.5 (range 2–11) years (table 1). Sixteen of the 22 families reported more than one case (median 2 (range 0–4)). Prior to hospitalisation, all patients had received antiepileptic drug treatment with phenobarbitone, phenytoin or carbamazepine with no clear documentation of benefit. Treatment had often been intermittent and at subtherapeutic doses.

Striking features on physical examination included stunting, cognitive impairment (on KABC or performance of basic tasks), lip changes and other physical deformities. Several children had burns and scars from burns. The skin was dry, thin and scaly. Extremities, especially the feet, felt cold with a temperature gradient with the trunk, but a normal capillary refill time. Among those with mild lip changes, the lower lip was enlarged with no visible or palpable localised swellings. In progressively more severe cases, the mucosa was deep purple, with soft papular growths and increasingly large, thick bands of tissue. One child, not exposed to sodium valproate previously, had unexplained alopecia.

Growth and sexual maturity

Sixteen of the 22 children were wasted and 9 stunted. Increasingly more severe wasting was observed with a longer duration of symptoms. Thus, patients with moderate wasting had symptoms lasting 3–6 years, while severe wasting was more common among those with symptoms lasting longer than 7 years. Ten had sexual maturity assessed; 3/10 children (aged 12, 13 and 14 years) scored Tanner stage 3. The remaining seven children (ages 12–17 years) were either Tanner stage 1 or 2. The bone age was delayed by a median 2 (range 1–6) years.

Musculoskeletal findings

Almost all had peripheral muscle wasting with progressively flat feet and hands, thin cylindrical digits and

Table 1 Characteristics of 22 patients with nodding syndrome

Age ID (years)	Duration of symptoms in yrs	Seizure based classification	Main Psychiatric morbidity	Other prominent complications	EEG seizure classification
1 14	11	Head nodding plus other seizures types	Behaviour problems Hallucinations	Severe cognitive impairment Burns Lip deformity Severe stunting, with severe wasting Spasticity and contractures with musculoskeletal deformities	Generalised epileptiform discharges
2 13	5	Head nodding plus other seizures types	Hallucinations aggressive behaviour	Moderate wasting	Generalised epileptiform discharges
3 15	10	Head nodding plus other seizures types	Behaviour problems Aggression Psychosocial disorder	Severe wasting Speech difficulties	Generalised epileptiform discharges
4 14	9	Head nodding only		Severe cognitive impairment Stunting	Generalised epileptiform discharges
5 16	9	Head nodding plus other seizures types	Aggressive behaviour Wandering Hallucinations	Severe cognitive impairment Speech difficulties Moderate wasting	Right temporal discharges
6 14	5	Head nodding plus other seizures types			Generalised epileptiform discharges
7 14	7	Head nodding plus other seizures types		Severe cognitive impairment Lip deformity Severe wasting	Generalised epileptiform discharges
8 18	10	Head nodding plus other seizures types	Aggressive behaviour Hallucinations	Severe cognitive impairment Speech difficulties	Generalised epileptiform discharges
9 18	8	Head nodding plus other seizures types	Psychotic symptoms Behavioural problems	Severe cognitive impairment Lip deformity Speech difficulties Severe wasting	Left temporal discharges
10 16	11	Head nodding plus other seizures types		Moderate wasting Burns Marked lip deformity	Generalised epileptiform discharges
11 15	9	Head nodding plus other seizures types	Depression	Hearing impairment Stunting Burns Musculoskeletal Deformities Severe cognitive impairment Severe wasting	Generalised epileptiform discharges
12 13	8	Head nodding plus other seizures types	Hallucinations		Generalised epileptiform discharges
13 13	3	Head nodding plus other seizures types		Moderate wasting	Generalised epileptiform discharges

Continued

Table 1 Continued

Age ID (years)	Duration of symptoms in yrs	Seizure based classification	Main Psychiatric morbidity	Other prominent complications	EEG seizure classification
14 14	9	Head nodding plus other seizures types	Hallucinations		Generalised epileptiform discharges
15 12	8	Head nodding plus other seizures types		Severe wasting Stunting Kyphosis, pectus deformity Generalised skin changes	Generalised epileptiform discharges
16 12	2	Head nodding only		Stunting Severe wasting	Generalised epileptiform discharges
17 14	8	Head nodding plus other seizures types	Post-ictal aggression Wandering	Severe cognitive impairment Stunting Lip deformity Ataxia Speech difficulties Spasticity and contractures with musculoskeletal deformities Moderate wasting Moderate wasting	Generalised epileptiform discharges
18 18	6	Head nodding plus other seizures types			Generalised epileptiform discharges
19 12	4	Head nodding only		Moderate wasting Stunting	Generalised epileptiform discharges
20 15	9	Head nodding only		Stunting	Generalised epileptiform discharges
21 15	9	Head nodding plus other seizures types		Severe cognitive impairment Lip deformity Speech difficulties Stunting Moderate wasting Spasticity with contractures and severe musculoskeletal deformity, wasting/dystrophy	Generalised epileptiform discharges
22 15	9	Head nodding plus other seizures types	Behavioural problems Aggression	Severe cognitive impairment Stunting Burns Episodes of disorientation Speech difficulties	Generalised epileptiform discharges

increasing generalised wasting. Other physical changes included kyphosis and pectus deformities of the chest. Flexion limb deformities were seen in patients with severe disability.

Neurological, cognitive and behavioural features

Seizures

Other than head nodding, a variety of other seizure types were described in 18/22 patients—including absence, complex partial, myoclonic and tonic-clonic seizures.

Head nodding

Nodding was precipitated by food in 16/22 children. In 4/22, it was associated with cold weather or a cold breeze, while in 13/22 it developed spontaneously. Nodding episodes came in clusters occurring during both the day and the night and were characterised by repetitive flexion and forward drop of the head. The clusters of head nodding lasted several seconds to minutes. Some children became unresponsive and stared blankly with each cluster of nodding, stopped feeding or drooled saliva.

Initially, head nodding was the predominant seizure type, but as the disease progressed, generalised tonic-clonic seizures became more prominent. Myoclonic seizures were not often reported, but were observed in several children while in hospital. One such child had a prolonged cluster of nodding with concurrent myoclonic jerks involving both upper limbs, lasting about 10 min. In a second child, similar myoclonic jerking was followed by a generalised tonic-clonic seizure. Several children had sudden falls, sustaining facial and head injuries.

Four children experienced paroxysmal events associated with fear, panic and visual hallucinations. We could not obtain clear descriptions of the images seen by two. The third child would shout and run with the onset of hallucinations and the fourth reported seeing a person with knives whose intention ‘was to kill her’. None of these events were captured on EEG.

Other neurological complications

Focal neurological signs were uncommon. There were no obvious cranial nerve palsies. However, six children

were lethargic with an apathetic and expressionless face or ‘myopathic facies’. Three of the six drooled saliva, while two had very slow speech and repeated epileptiform (spike and wave) discharges on EEG. The deep tendon reflexes were increased in a minority of patients. In the majority, however, the reflexes were either normal or reduced.

Vision, hearing and speech difficulties

No parent reported visual impairment and we did not test visual acuity, but hearing impairment was reported in one child. Speech difficulties were reported in 10/22 children. These included immature speech for age and slow, slurred or dysarthric speech. Two children were mute, but retained gestural ability and receptive language.

Behaviour and psychiatric features and complications

The earliest psychiatric manifestation was the wandering behaviour or running away. Owing to the concerns about injury or getting lost, some parents tied up the patients to restrain them at home. Aggression, particularly towards familiar people, was reported in 6/22 cases, manifesting 3–6 years after onset of nodding. In two children, the onset was concurrent with wandering behaviour. Five children had sleeping difficulties and at least 8/22 had moderate-to-severe mood problems with one clinically depressed.

Cognitive function

All 22 children had cognitive difficulties and were out of school. Academic performance declined with symptom onset; as symptoms increased, pupils started getting poorer grades and were eventually withdrawn from school within 2–4 years of disease onset. Three of the four children who had cognitive functioning assessed using the KABC-2 responded to the test instructions. The fourth child did not respond at all. All three children had severe cognitive impairment (table 2).

Laboratory findings

The mean haemoglobin was 12.4 (range 10.8–14.8) g/dl and the mean red cell volume was 81.4 (range 65.8–

Table 2 Cognitive function on the Kaufman Assessment Battery for Children 2nd Edition in three children 2 weeks after initiation of sodium valproate

Cognitive domain	Patient 1		Patient 2		Patient 3	
	Male 13 years		Male 15 years		Male 15 years	
	Test score	Age equivalent in years	Test score	Age equivalent in years	Test score	Age equivalent in years
Working memory	8	<5	7	<5	21	=5
Planning	7	<8	1	<5	3	<5
Learning	28	<5	25	<5	54	=5
Visual spatial	0	<5	0	<5	31	<5
Knowledge	11	<5	5	<5	52	<8

89.1) fl. Five children had iron deficiency anaemia. The total white blood cell and platelet counts were normal, but 10/22 children had eosinophilia: median eosinophil count 0.4 (range 0.1 – 1.9) $\times 10^9/l$. The ESR was high in 17/22 children with a median of 28.5 (range 5 – 90) mm in the first hour. Other than mild elevations of γ GT, the liver and renal functions were normal. All tested negative for malaria on admission to Mulago, although one subsequently developed malaria in the third week of hospitalisation. Nine children had osteopenia on x-ray, but only one had hypocalcaemia and four hypophosphataemia. Creatine kinase levels were normal in all children and all tested HIV negative. Cerebrospinal fluid total protein, cells and glucose were all normal and all bacteriological cultures had no growth. Three of 10 patients had *O. volvulus* microfilaria on the skin snip. Microfilaria density was, however, not reported.

EEG

The routine diagnostic EEG was abnormal in all cases. The background activity showed a generalised excess of slow activity mainly in the conventional θ and δ frequency ranges. Generalised interictal epileptiform activity was observed in all, but two patients, in whom there were focal temporal discharges (unilateral in one and bilateral in the second). All patients with generalised epileptiform activity had high-amplitude spikes or sharp waves, some associated with slow wave activity and often occurring in irregular bursts rather than runs (figure 1). There was no consistent frequency to this. The discharges had bilateral frontotemporal or frontocentrotemporal emphasis, but some were more generalised and increased in frequency in light sleep. There was a clear gradation from mild to more severe background abnormalities and epileptiform activity. No overnight recordings were performed. The EEG findings suggested symptomatic generalised epilepsy in 20 and symptomatic focal epilepsy in the remaining 2.

Brain imaging

Brain MRI without contrast was performed in 19/22 patients. The imaging showed different degrees of cortical and cerebellar atrophy. No focal cerebral cortical or hippocampal changes were observed (figure 2). Cerebellar disease was evident in the majority of cases; but among patients with especially generalised cortical atrophy, there was a suggestion of more atrophy in the occipital lobes or the parieto-occipital regions than anteriorly.

Disease progression

Five stages with deteriorating seizures, neurocognitive and psychiatric disability were identified: a prodrome; development of head nodding and cognitive impairment; other seizure types; multiple complications and severe debilitation (box 1).

Stage 1: prodromal period

This poorly defined and short-lived period was reported in four patients. The earliest symptoms included “dizziness” and increasing inattention. The children were excessively sleepy, lethargic and would sometimes stare blankly during meals.

Stage 2: development of head nodding

Among the four patients reporting prodromal symptoms, head nodding developed within 6 weeks of the prodrome. In the majority, however, the initial feature was an abrupt onset of nodding. Subsequently, the parents reported declining cognitive abilities and behaviour difficulties. Disease progression, however, appeared to be arrested in these four.

Stage 3: development of other seizure types

Apart from the four children with nodding only, 18 children developed other seizure types including absence, complex partial, myoclonic and generalised tonic–clonic seizures. One child developed generalised tonic–clonic seizures almost simultaneously with the nodding. In the others, however, additional seizure types developed 1–3 years after initial symptoms. It was around this time that almost all school-going children dropped out of school.

Stage 4: development of multiple complications

Multiple complications developed 4–8 years after the initial symptoms, associated with marked regression in achievement. These consisted of deteriorating behaviour and psychiatric symptoms and a decline in motor, speech and other cognitive functions. Some patients developed physical deformities including kyphosis, limb and pectus deformities. Some sustained severe facial injuries with ‘drop attacks’ and burns. Those who were still independently mobile would wander about or run away and were prone to getting lost. Changes in the architecture of the lower lips also occurred at this time. With disrupted and poor feeding, the children became severely wasted.

Stage 5: severe disability

These children have little, if any, independent mobility. The general picture is that of a severely wasted child with apathy and depressive features including a flat affect, poor appetite and limited speech. Some had contractures around the major joints.

Patients with head nodding only had less cortical and cerebellar atrophy on brain MRI compared with those with multiple complications. In addition, there was a clear gradation from milder to more severe epileptiform and background EEG abnormalities in patients with the later clinical stages of the disease.

Response of seizures to sodium valproate

The patients had previously been on mostly low doses of various antiepileptic drugs including phenytoin, phenobarbitone and carbamazepine. In conformity with the

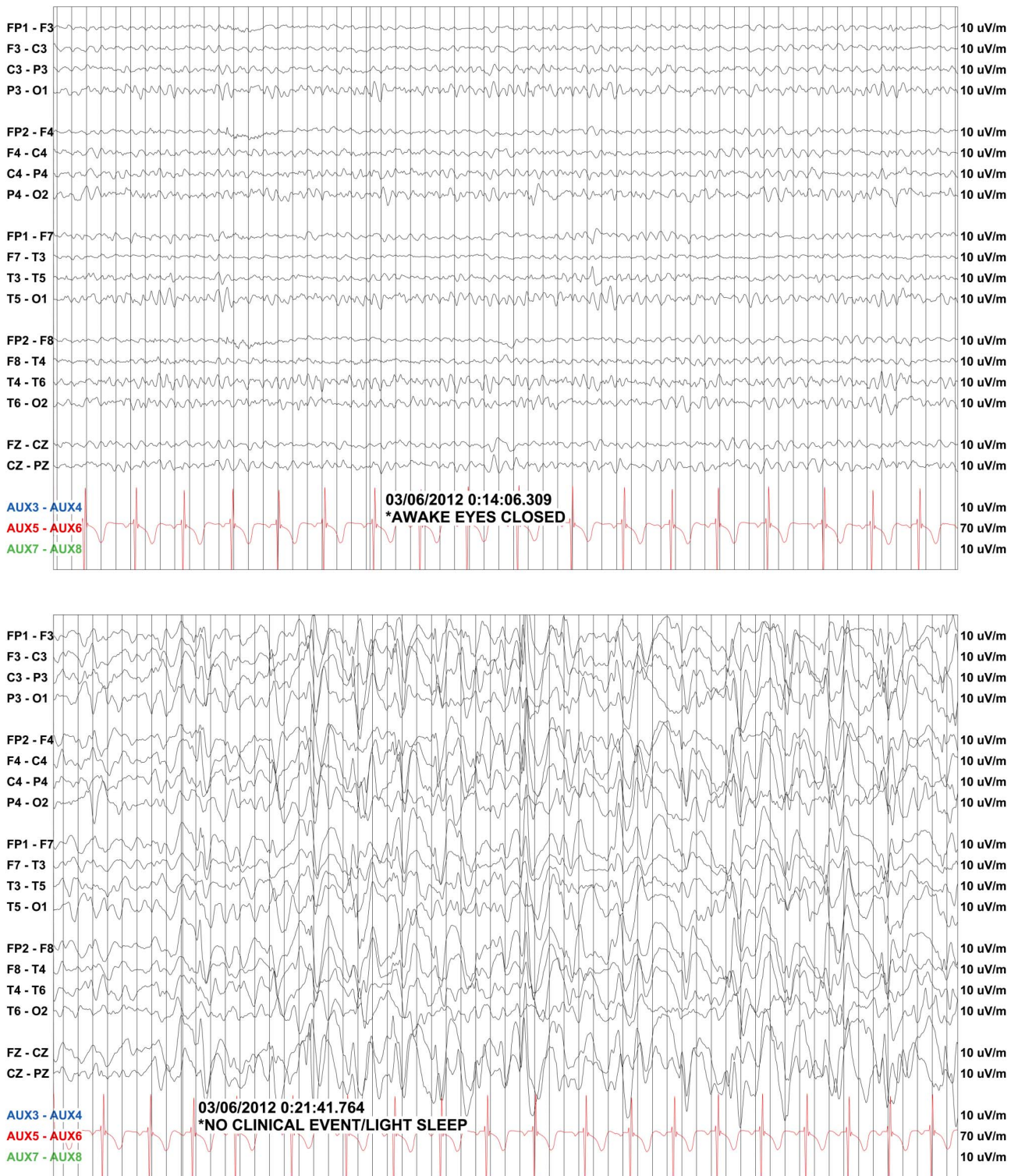


Figure 1 EEG recordings. An EEG recording of a 12-year-old girl. She had head nodding and cognitive impairment. During the recording, interictal epileptiform discharges (spikes and sharp waves) were observed in wakefulness (A) and during light sleep, when more prominent epileptiform discharges were evident. There was no apparent clinical change with these discharges (B).

proposed national guidelines, all were started on sodium valproate and the other antiepileptic drugs weaned off. Prior to this, a 24 h seizure count was obtained and this was repeated 14 days later. Overall, there was a 57%

reduction in total seizures including clusters of nodding. The median total daily number of seizures reduced from 5 (range 2–14) on admission to 2 (range 0–8) 14 days after initiation of sodium valproate. Concurrent

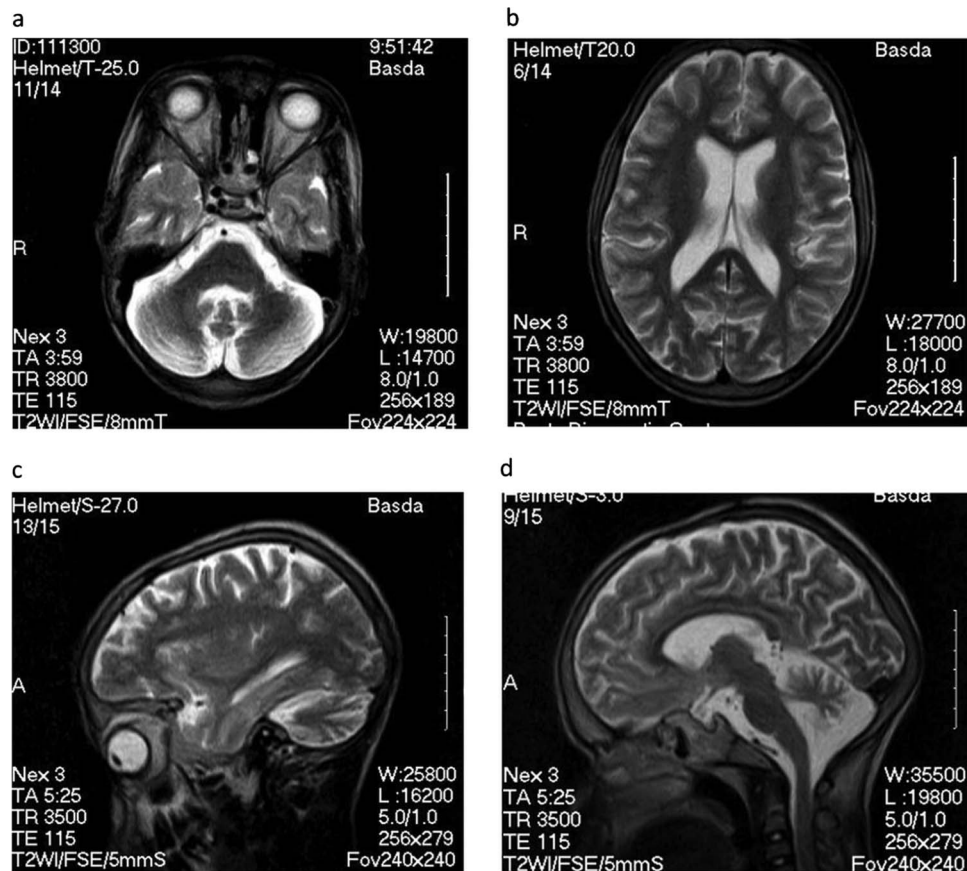


Figure 2 Brain MRI. T2-weighted brain MRI in the axial (A and B) and sagittal (C and D) plane showing marked cerebellar atrophy and generalised cerebral atrophy.

improvements were also seen on the EEG with substantially reduced or absent interictal discharges in 3/5 patients who had repeat recordings on the day of assessment (figure 1).

Box 1 A mum's description of the sequential chronology of symptoms and disease progression in her 18-year-old daughter

She was growing well until the age of 8 years when symptoms of nodding began. The head nodding is triggered by food. When food is given, she freezes with it in her hand, stares blankly into space with a fixed gaze, and then nods repeatedly for a time which varies with each episode but the maximum time was initially 5 minutes. The symptoms got worse with time and about 6 years later, the nodding symptoms were immediately followed by or associated with big seizures during which the whole body shook. She would drool saliva, foam around the mouth and loses consciousness. After the big seizure, she would sleep and on waking is often weak and sometimes disoriented. On some nights, she reports seeing a figure that holds a knife and wants to kill her. She is distressed by her illness and gets embarrassed on waking if she had a seizure in public. She is very quiet but sometimes aggressive. Overtime, her speech has become sluggish. Although she is 18 years old, she still has childish behaviour which is evident as she speaks. Her father died following a febrile illness. She has six siblings two of who have similar symptoms.

DISCUSSION

Recently, there have been media reports of 'a mysterious disease' baffling scientists—the nodding syndrome.^{7 23 24} There are many uncertainties about this newly recognised disorder: what is the cause, the pathogenesis, disease classification, clinical spectrum and treatment? In this paper, we describe the clinical features and complications of nodding syndrome in Ugandan children, together with the EEG and brain imaging appearances. Our findings suggest that nodding syndrome is a neurological disorder characterised by a symptomatic generalised epilepsy.

Clinical features and complications

Nodding syndrome in Ugandan children manifests with head nodding, cognitive dysfunction, psychiatric features and/or multiple seizure types. It may be complicated by stunted growth, pubertal delay, wasting, motor decline and physical deformities. The earliest manifestation is a poorly defined prodrome followed within weeks by head nodding. In the later stages, there is cognitive dysfunction, psychiatric disturbance and severe muscle wasting and musculoskeletal deformity. Delayed physical growth, bone age and sexual maturity are common in affected children. This may partly be a result of delayed puberty, since most were in Tanner stage 2. Pubertal delay may be secondary to chronic illness, poor nutrition and/or

psychosocial deprivation. If so, improved nutrition, a supportive environment and symptom control should lead to improved growth and the initiation of puberty.

The progressive stages of the disorder appear to reflect the natural progression of an epileptic encephalopathy. In stage 1, there are brief seizures; while by stage 3, uncontrolled seizures prevent the child from continuing in school. In stage 4, a high seizure burden contributes to regression, which together with ensuing poor nutrient intake leaves a severely disabled child by stage 5, when multiple factors impair functioning.

The clinical features in Ugandan children are as severe as in South Sudanese children,⁶ but may be more severe than in Tanzanian patients.⁹ Despite similar age of onset and duration of symptoms, only 18% of Ugandan children had the milder nodding only variant, compared with 45% in Tanzania; all our patients had abnormal interictal background EEG compared with 60% in Tanzania. Ugandan children also had more severe cognitive impairment and a much greater burden and variety of seizures. These differences may suggest a variation in the presentation of the disease by region. Family clustering in all three countries, however, suggests a common exposure factor.

Aetiology and pathogenesis

The aetiology of nodding syndrome and pathogenesis of the complications remain unknown. A variety of viral central nervous system infections have been screened for on PCR, but no association has been demonstrated.¹⁹ An association with infestation with *O. volvulus* has been reported in some series,^{5, 9} but has not been evident in other studies.^{18, 25} Other aetiological considerations have included toxic brain injury, inflammatory brain disease, a slow virus infection or prion disease, an atypical mitochondrial disease or other genetic disorders. Repeated severe psychological trauma has also been proposed as a mechanism.²⁶ Earlier studies by the Ugandan Ministry of Health and the US Centers of Disease Control found a higher proportion of cases with low serum vitamin B₆ compared with controls. Although unlikely, the possibility was raised that nodding syndrome could be an atypical form of pyridoxine dependent epilepsy. Studies to explore this hypothesis further are awaited.²⁷

Children with this syndrome show some features reminiscent of prion protein disease, including motor and cognitive dysfunction, epilepsy, behaviour and psychiatric morbidity. However, other features commonly seen in prion disease—such as extrapyramidal involvement and cortical blindness—have not been reported. The age of onset of symptoms is also much younger and progression is much slower.²⁸ The brain imaging and EEG findings too are not suggestive of prion disease. Nevertheless, brain biopsy or autopsy studies would be important in excluding prion disease.

The brain MRI findings might suggest viral encephalitis, a para-infectious phenomenon (such as an antibody-mediated channelopathy) or even a neurotoxin as

possible aetiologies. A genetic disorder or metabolic disease is also possible. Future studies should also consider the recently described autoimmune encephalitides. Among Tanzanian patients, hippocampal sclerosis, probably from inflammation, was described in some patients.⁹ Although this could partly explain the cognitive difficulties, we did not observe such lesions, even in the subgroup with more severe cognitive impairment. We consider that an epileptic encephalopathy is more likely. The background EEG in all 22 cases showed a generalised excess of θ and slow activity. Prolonged EEG recording (including during sleep) with detailed neuropsychological testing and functional brain imaging may help in understanding the pathogenesis of cognitive decline.

Study limitations

Our patients may not be a representative sample, as they were not drawn randomly from the community. The study did not investigate aetiology and the proposed staging was derived primarily from parental descriptions rather than prospective observations and so may be influenced by recall bias. We only performed routine diagnostic EEGs, rather than prolonged recordings which are important in investigating associations between seizures and cognitive dysfunction. The resolution of our MRI is also quite low.

CONCLUSIONS

Nodding syndrome is a neurological disorder that is complicated by multiple physical and functional disabilities and may be considered as symptomatic generalised epilepsy. Assessment and care should be provided by a multidisciplinary team. Studies of aetiology, pathogenesis, evidence-based treatment and rehabilitation strategies are urgently needed.

Author affiliations

¹Department of Paediatrics, Mulago Hospital/Makerere University College of Health Sciences, Kampala, Uganda

²Nuffield Department of Medicine, Centre for Tropical Medicine, Oxford University, Oxford, UK

³Department of Psychiatry, Mulago Hospital/Makerere University College of Health Sciences, Kampala, Uganda

⁴Department of Internal Medicine, Mulago Hospital/Makerere University College of Health Sciences, Kampala, Uganda

⁵Department of Clinical Neurophysiology, Great Ormond Street Hospital for Children, London, UK

⁶Department of Neuroradiology, Great Ormond Street Hospital for Children, London, UK

⁷Department of Community Health and Family Medicine, Mulago Hospital/Makerere University College of Health Sciences, Kampala, Uganda

⁸Ministry of Health Head Quarters, Kampala, Uganda

Acknowledgements We would like to thank Dr Aggrey Dhabangi, Dr Ruth Lanyero, Dr Betty Lanyero and Dr Odong Ochaya who helped with the daily clinical care, the nursing team of Acute Care Unit where the children were resident and Dr Faith Ameda who reported the x-rays. We also thank Professor Charles Newton and Professor Chandy John, who read through the draft manuscript and offered valuable comments to improve it.

Contributors RI, ROO, AK-M, HAT, TP-W, PB, JN1, SBM, ADM, HN, EM, JN2, SK, JRA and JKT all participated in patient care and performed the different assessments. ROO, AK-M, HAT and SBM were in-charge of daily care, TP-W and EM performed the growth and sexual staging assessments, JN1 the psychiatric assessments, HN the nutrition assessment, SW reported the EEG recordings, KC the brain MRI and RI wrote the first draft. All provided a critical review of the manuscript.

Funding This work was supported by the Government of Uganda through the Ministry of Health and by the Waterloo Foundation through grant number 1025/1490 to Dr Idro. The funding agency had no role in data collection, analysis and interpretation of the results and in the decision to submit for publication.

Competing interests None.

Ethics approval Makerere University School of Medicine Research and Ethics Committee.

Provenance and peer review Not commissioned; externally peer reviewed.

Data sharing statement No additional data are available.

REFERENCES

- Korevaar DA, Visser BJ. Reviewing the evidence on nodding syndrome, a mysterious tropical disorder. *Int J Infect Dis* 2013;17:e149–52.
- Aall L. Epilepsy in Tanganyika. *Review and Newsletter- Transcult Res Mental Hlth Probl* 1962;13:54–7.
- Goudsmit J, van der Waals FW. Endemic epilepsy in an isolated region of Liberia. *Lancet* 1983;1:528–9.
- Lacey M. Nodding disease: mystery of southern Sudan. *Lancet Neurol* 2003;2:714.
- Centers of Disease Control. Nodding syndrome—South Sudan, 2011. *MMWR Morb Mortal Wkly Rep* 2012;61:52–4.
- Nyungura JL, Akim T, Lako A, et al. Investigation into the Nodding syndrome in Witto Payam, Western Equatoria State, 2010. *South Sudan Med J* 2011;4:3–6.
- Wasswa H. Ugandan authorities deal with a mysterious ailment that leaves people nodding continuously. *BMJ* 2012;344:e349.
- Sejvar JJ, Kakooza AM, Foltz JL, et al. Clinical, neurological, and electrophysiological features of nodding syndrome in Kitgum, Uganda: an observational case series. *Lancet Neurol* 2013;12:166–74.
- Winkler AS, Friedrich K, Konig R, et al. The head nodding syndrome—clinical classification and possible causes. *Epilepsia* 2008;49:2008–15.
- Winkler AS, Friedrich K, Meindl M, et al. Clinical characteristics of people with head nodding in southern Tanzania. *Trop Doct* 2010;40:173–5.
- Wendo C. Northern Uganda humanitarian crisis shocks UN chief. Rebels in northern districts have left people trapped in hunger, disease, poverty, and fear. *Lancet* 2003;362:1818.
- Leonard PJ, Stanfield JP. Some biochemical observations in the Nakalanga. *East Afr Med J* 1965;42:692–4.
- Jelliffe DB, Jones PR, Stroud CE. Nakalanga notes on the endemic dwarfism of Uganda. *Trop Geographical Med* 1962;14:97–104.
- Marshall AJ, Cherry JK. Endocrine dysfunction in a Nakalanga dwarf. *Trans R Soc Trop Med Hyg* 1961;55:188–91.
- Kipp W, Burnham G, Bamuhiiga J, et al. The Nakalanga syndrome in Kabarole District, Western Uganda. *Am J Trop Med Hyg* 1996;54:80–3.
- Kipp W, Kasoro S, Burnham G. Onchocerciasis and epilepsy in Uganda. *Lancet* 1994;343:183–4.
- Pion SD, Kaiser C, Boutros-Toni F, et al. Epilepsy in onchocerciasis endemic areas: systematic review and meta-analysis of population-based surveys. *PLoS Neglected Trop Dis* 2009;3:e461.
- Konig R, Nassri A, Meindl M, et al. The role of *Onchocerca volvulus* in the development of epilepsy in a rural area of Tanzania. *Parasitology* 2010;137:1559–68.
- WHO. *International scientific meeting on nodding syndrome*. Designation of the illness. Geneva: World Health Organization, 2012:1–42.
- Acheson RM, Fowler G, Fry EI, et al. Studies in the reliability of assessing skeletal maturity from X-rays. I. Greulich-Pyle Atlas. *Hum Biol* 1963;35:317–49.
- Bangirana P, Seggane M, Allebeck P, et al. A preliminary examination of the construct validity of the KABC-II in Ugandan children with a history of cerebral malaria. *Afr Health Sci* 2009;9:186–92.
- A Ugandan Ministry of Health document. Session 2.1: Surveillance for Nodding Syndrome in: *Nodding syndrome; health workers training manual*. Draft Edition; February 2012 edn. Kampala: Ministry of Health, 2012:1–107.
- Williams SC. Nodding syndrome leaves baffled scientists shaking their heads. *Nat Med* 2012;18:334.
- Edwards J. Nodding disease confounds clinicians. *CMAJ* 2012;184.
- Twum-Danso NA. Mass treatment of onchocerciasis with ivermectin: should people with epilepsy and/or growth-retardation syndromes be excluded? *Ann Trop Med Parasitol* 2004;98:99–114.
- Nodding disease in northern Uganda—a possible relationship to psychotrauma. *7th MakCHS Annual Scientific Conference, 19th UNACOH Annual Scientific Conference, 10th Who DR. Mathew Lukwiya Memorial Lecture*; 2011; Speke Resort, Munyonyo, Kampala, Uganda. Makerere University College of Health Sciences.
- Donnelly J. CDC planning trial for mysterious nodding syndrome. *Lancet* 2012;379:299.
- Wadsworth JD, Collinge J. Update on human prion disease. *Biochim Biophys Acta* 2007;1772:598–609.